

Pakistan Comprehensive Fistula Classification: A Novel Scheme and Algorithm for Management of Palatal Fistula/Dehiscence

Ghulam Qadir Fayyaz,

M.B.B.S., D.S.S., M.S.

Nauman Ahmad Gill,

M.R.C.S., F.C.P.S.

Irfan Ishaq, M.B.B.S.

Muhammad Aslam,

M.B.B.S., F.C.P.S.

Ayesha Chaudry, M.B.B.S.,

F.C.P.S.

Muhammad Ashraf Ganatra,

M.B.B.S., M.S.

Obaidullah Obaid, F.R.C.S.

Moazzam Nazeer Tarar,

F.R.C.S.

Philip Kuo-Ting Chen, M.D.

Donald Rudolph Laub, M.D.

Lahore, Punjab, Karachi, and

Peshawar, Pakistan; Taipei, Taiwan;

and Stanford, Calif.



Background: It is not easy to find a management-based classification of palatal fistula in the literature. A few attempts have been made to classify the wide variety of fistulae that do not describe the fistula details comprehensively and guide toward its management. The authors have come across a wide variety of fistulae that could not be classified according to any of the prevailing classification systems. The presented classification gives a clear and exact understanding of location and size of fistula/dehiscence. Palatal function has been included as one of the important determinants for devising a management plan. Based on this classification, the authors have proposed an algorithm that encompasses clear guidelines for surgical treatment of these fistulae.

Methods: Over the past 15 years, the authors' team operated on 2537 palatal fistula patients. The medical records of these patients were reviewed to determine the location, size, and velopharyngeal competence. A new classification and algorithm were developed.

Results: Of 2537 patients, 2258 had midline fistulae, 208 had lateral fistulae, and 53 had subtotal fistulae. There were 18 patients with dehiscence. Recurrence developed in 181 patients.

Conclusion: The authors believe that this classification and algorithm can help follow a practical approach to manage palatal fistulae and dehiscence. (*Plast. Reconstr. Surg.* 143: 140e, 2019.)

Palatal fistula is one of the most common complications of palate repair, with rates reported as high as 60 percent.¹ Type of cleft palate, width of the cleft, method of cleft palate repair, and expertise of the operating surgeon may be contributing factors.² The highest rate of fistula has been reported for bilateral complete cleft palate.³ Assessment and treatment of palatal fistulae is of prime importance because of the structural and functional impairment of palate.⁴ A few classification systems have been described in the literature, but none of them clearly elaborates the nature of the fistula, its impact on the function of the palate, the number of fistulae, fistula position, and the complexity of reconstruction required. In developed countries, rates of fistula are low at designated cleft centers.⁵ In

the rest of the world, because of the lack of proper facilities and resources, the fistula rates are quite variable.⁶ During charity funded "cleft missions" in developing countries, a wide variety of fistulae are often encountered. The reasons are multiple and include many factors, such as suboptimal operating conditions, wide cleft palates, and different surgeons with varying capabilities using different techniques.

We have devised a novel system of classification for defining and describing palatal fistulae based on the location (L), size (S), velopharyngeal competency (V), and dehiscence (D) if any. Based on

Disclosure: The authors have no financial interest to declare in relation to the content of this article.

Supplemental digital content is available for this article. Direct URL citations appear in the text; simply type the URL address into any Web browser to access this content. Clickable links to the material are provided in the HTML text of this article on the *Journal's* website (www.PRSJournal.com).

From the Services Institute of Medical Sciences; Dow University of Health Sciences; North West Hospital; Jinnah Burns and Reconstructive Surgery Center; Taipei Medical University Hospital; and Stanford University.

Received for publication October 18, 2017; accepted May 25, 2018.

Copyright © 2018 by the American Society of Plastic Surgeons

DOI: 10.1097/PRS.00000000000005169

this classification, we have proposed an algorithm for the management the fistulae. We believe that this classification system and algorithm would be of great help in documentation of any fistula and planning of the most appropriate surgical procedure for its reconstruction.

PATIENTS AND METHODS

A retrospective review of all patients presenting with palatal fistula over the past 15 years (2002 to 2017) was performed at CLAPP Hospital Lahore, Lahore, Pakistan. In addition to demographic variables, location (in terms of midline, lateral, or subtotal), size (measured in millimeters) and velopharyngeal function (speech assessed by Mary Burger speech scale) were noted in each patient. The surgical management undertaken and postoperative results were recorded and, based on these findings, a new classification of fistulae was developed.

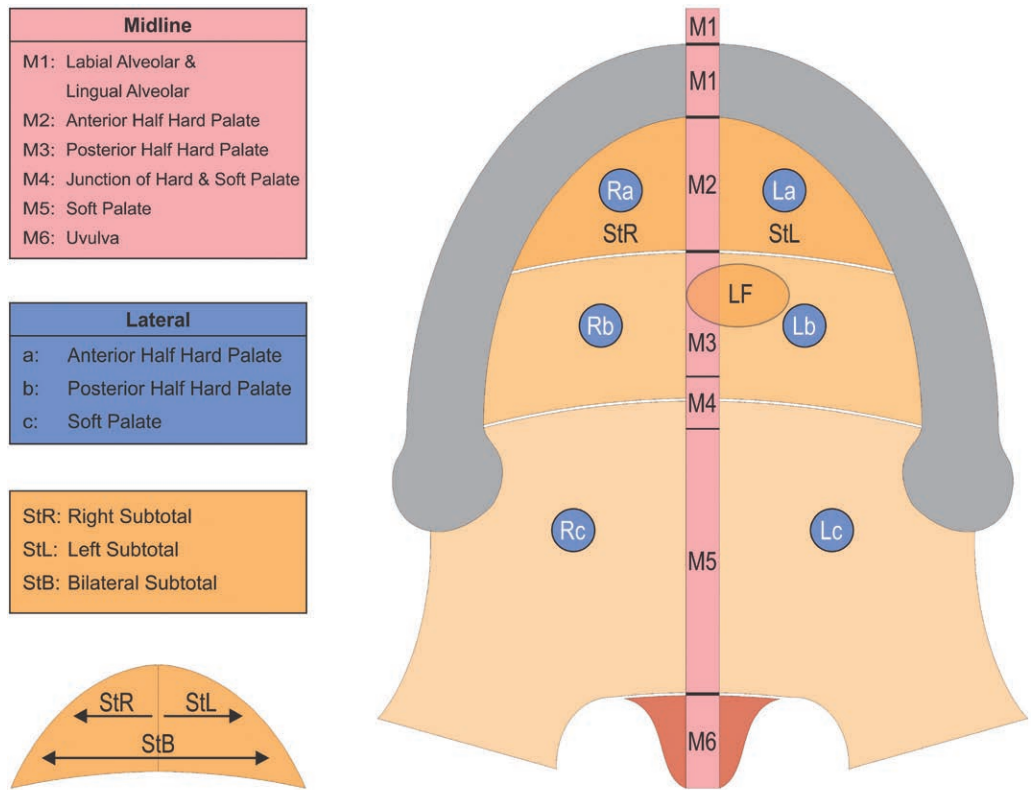
Classification

Our classification system is based on three main characteristics of the palatal fistula: location,

size, and velopharyngeal competence (Fig. 1), and dehiscence if any (Fig. 1). These features describe any palatal fistula and thus help plan its further management. The location of the fistula can be midline (M) or lateral (L). A fistula is called a midline fistula if greater than 50 percent of its transverse diameter is located within 1 cm of the midline (5 mm on each side of midline). The midline fistulae can be further subdivided into six zones starting from anterior to posterior as shown in Figure 1. If a fistula is large enough to cover two or more zones (such as M2, M3, and M4) in the midline, it would be called a fistula adjacent region, and the involved zones are mentioned along with the letter M (e.g., M2-M3-M4).

A fistula is called a lateral fistula if greater than 50 percent of the width of the fistula is located outside the 1-cm midline zone. The lateral fistulae are further subdivided into “a” (anterior half of hard palate), “b” (posterior half of hard palate), and “c” (soft palate).

If any anterior fistula extends from the midline to the lateral side and involves 50 percent or



LF: A fistula involving the midline as well as lateral side of the palate and if more than 50% of the transverse width of the fistula is away from the midline, it will be labeled as lateral fistula (LF).

Fig. 1. Schematic diagram showing location of different fistulae.

more of the hard palate, it is called a subtotal fistula. The subtotal fistulae are StR (right subtotal), StL (left subtotal), and StB (bilateral subtotal). These fistulae indicate damage to either one or both greater palatine arteries resulting in loss of anterior palatal tissues.

The size of the fistula is the next determinant of severity, because larger fistulae in any region increase the difficulty of closure. The fistula size can range from S1 (1 to 5 mm) to S4 (>15 mm) (Fig. 2). Final determinant in the management of palatal fistulae is any functional impairment of the soft palate as assessed by a speech pathologist (velopharyngeal competency). We have categorized this function into three types. V1 is the palate in which length is adequate and has good movement. If length of the palate is adequate but the movement is poor, we call it V2. In those cases where the length of the palate is short and movement is poor as well, we call it V3.

If there are multiple fistulae, it will be written as MF (multiple fistulae) and the individual fistulae will be mentioned from anterior to posterior as F1, F2, or F3. Further description of location and size of each fistula will be mentioned along with the specific fistula, whereas velopharyngeal competence will remain the same.

In certain situations, dehiscence may be encountered with or without the fistula (Fig. 3). We describe the dehiscence starting from posterior to anterior as D1 to D4. Please note that if the uvula is intact, it should not be called dehiscence. If there is dehiscence of the uvula, it is called D1. If the dehiscence extends into the soft palate, it is named D2. Any dehiscence involving uvula, soft palate, and posterior half of the hard palate should be termed D3. If there is complete dehiscence of the hard and soft palate, we call it D4. There may be loss of the lateral part of one of the mucoperiosteal flaps resulting in extension of dehiscence to that side of the palate. Such a dehiscence should be called D3L/R (left/right) if posterior half of the hard palate is involved.

We propose that the palatal fistula can be described by three letters: L, S and V. Using these three letters description, it is easier to comprehend the characteristics of palatal fistula. A few examples are shown in the figures with their classification.

Management

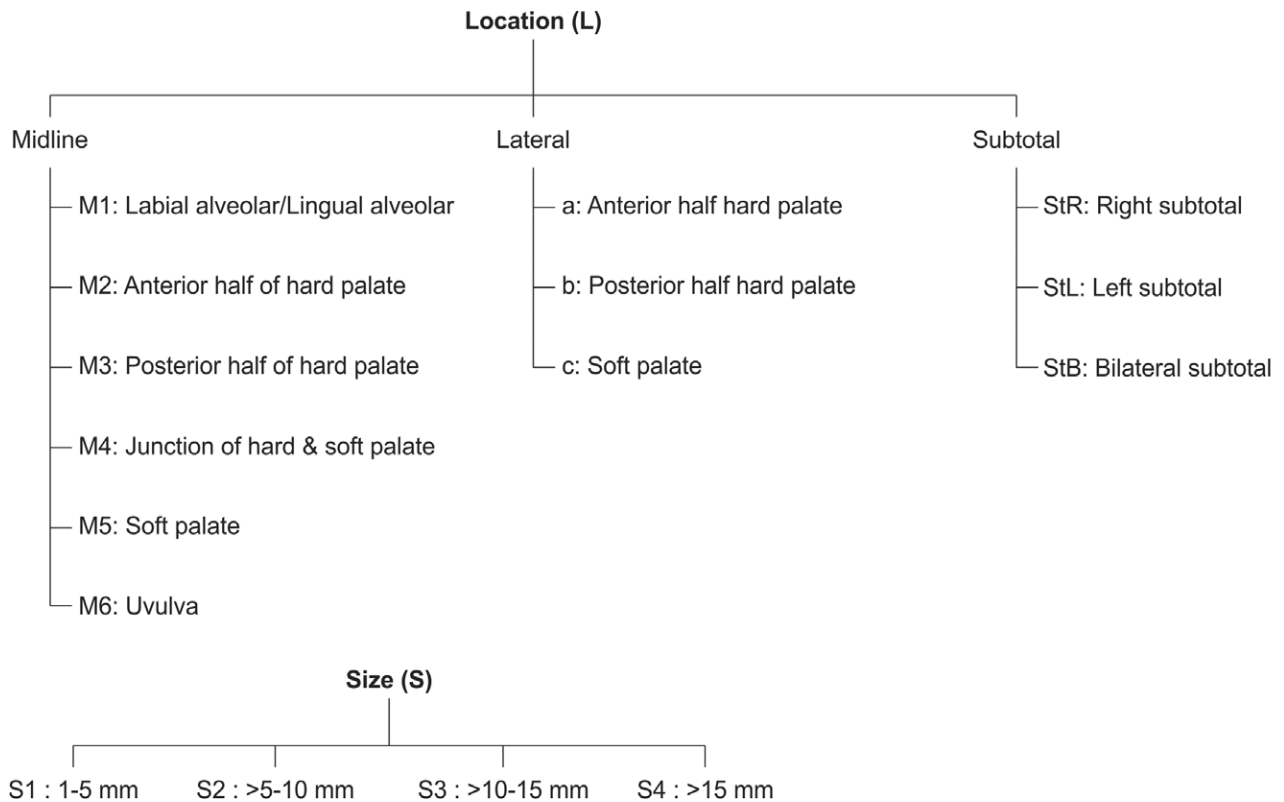
We have proposed an algorithm based on our experience (Fig. 4). Most fistulae occur in the midline and are the result of excess tension on the suture line. If function of the soft palate

is good, the aim of treatment is simple closure of the fistula in two layers. Anteriormost fistulae in the midline (M1-labioalveolar or lingual-alveolar) are usually small, and simple closure of the nasal layer by turn-in flaps and oral layer closure by buccal sulcus mucosal flap can suffice (Fig. 5). Midline fistulae in the region of the hard palate (M2 or M3) are also usually small. In these cases, mucoperiosteal flaps can be raised on both sides (after nasal layer closure) and mobilized to cover the midline defects (Fig. 6). If function of the soft palate is adequate, no other procedure is needed. If function of the soft palate is inadequate (V2) as reported by the speech pathologist, complete rerepair of the palate has to be performed so that proper retropositioning of the soft palate musculature is carried out to improve the function of the soft palate. In certain cases, the length of the soft palate is short as well (V3). A pharyngeal flap may then be required to increase the length of the soft palate in addition to palate rerepair.

The area of M4 (junction of hard and soft palates) deserves special attention, as a fistula occurring in this region indicates problems with inadequate dissection and mobilization during initial surgery. For repair of such fistulae, rerepair of the palate with radical dissection of the greater palatine artery, muscle dissection, and retropositioning has to be carried out (Fig. 7). If the length of the soft palate is short (V3), a pharyngeal flap may be added. In the region of the soft palate (M5), closure of a fistula is relatively easy (Fig. 8). The nasal layer can be closed with a turn-in flap and oral layer closure can be performed using adjacent palatal tissues. If function of the soft palate is inadequate (V2 or V3), a pharyngeal flap has to be added. Depending on personal experience and preference, other surgeons may opt for the Furlow double-opposing Z-plasty or oricochea pharyngoplasty, although we prefer the pharyngeal flap. Similarly, a fistula in the uvula (M6) can be managed by closure in two layers.

If a longitudinal fistula involves more than one zone in the midline, a similar principle of closing the nasal layer with turn-in flaps and oral layer closure with mucoperiosteal flaps can be carried out. [See **Figure, Supplemental Digital Content 1**, which shows a 26-year-old man with a very large midline fistula involving M2, M3, M4, and M5, approximately 32 × 12 mm, with poor movement of the soft palate (M2,3,4,5 S4 V3). Repair of the palate with palate rerepair and addition of the pharyngeal flap, <http://links.lww.com/PRS/D212>.] In addition, muscle retropositioning with

Pakistan Fistula Classification, A Novel Scheme and Algorithm for Management of Palatal Fistula/Dehiscence



Velopharyngeal Competency (V)

- V1 : Adequate length of soft palate with good movement
- V2 : Adequate length of soft palate with poor movement
- V3 : Short length of soft palate poor movement

Dehiscence (D)

- D1: Dehiscence of uvula
- D2: Dehiscence of soft palate
- D3: Dehiscence up to posterior half of hard palate (L or R)
- D4: Dehiscence of complete palate (L or R)

MF: Multiple Fistulae
 F1; Anterior-most Fistula
 F2;
 F3 and so on
 FAR: Fistula (Involving) Adjacent Regions
 Like M2-3-4

Fig. 2. Description of different types of fistula and dehiscence.

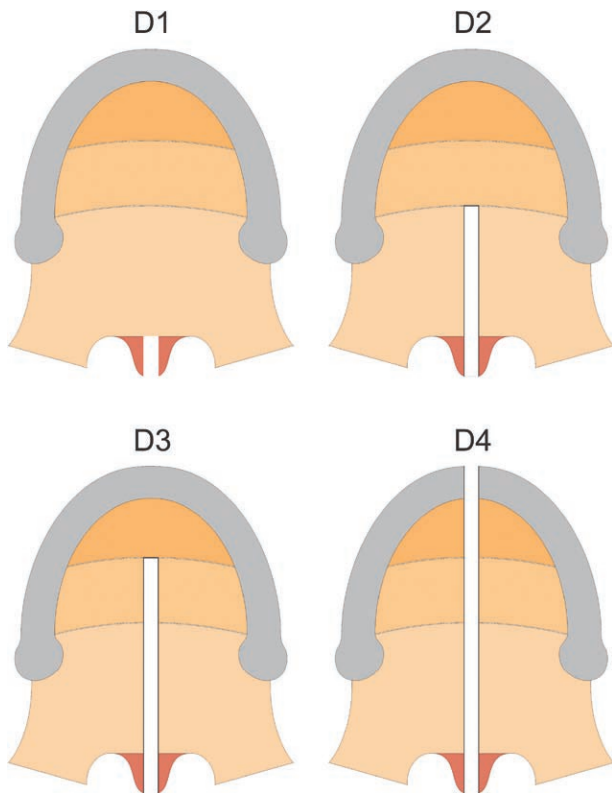


Fig. 3. Schematic diagram showing the different types of dehiscence.

or without pharyngeal flap may have to be performed, depending on the status of function of the velum.

Regarding the management of lateral fistulae, small fistula (S1) of the anterior hard palate (Ra or La) can be treated with nasal layer closure by turn-in flaps and oral layer closure by contralateral mucoperiosteal flap (Fig. 9). If movement of the soft palate is poor (V2), rerepair of the palate with palatal muscle mobilization and repositioning has to be carried out as well. In case the soft palate is short as well (V3), we incorporate a pharyngeal flap to improve soft palate function. For larger fistulae of this region (S2 and S3), we may need to provide oral layer closure with regional tissue flaps such as facial artery myomucosal, tongue, cheek mucosal, and other flaps.

Lateral palatal fistulae in the posterior half of the hard palate are usually rare, but their management is even more difficult. A large turn-in flap is required for nasal layer closure. Oral layer closure can be achieved with a contralateral mucoperiosteal flap (Fig. 10) or regional tissue flaps such as a facial artery myomucosal flap or a tongue flap. If function of the soft palate is inadequate (V2 or V3), palate rerepair with or without a pharyngeal flap may have to be added. Lateral palatal fistulae in the region of

ALGORITHM

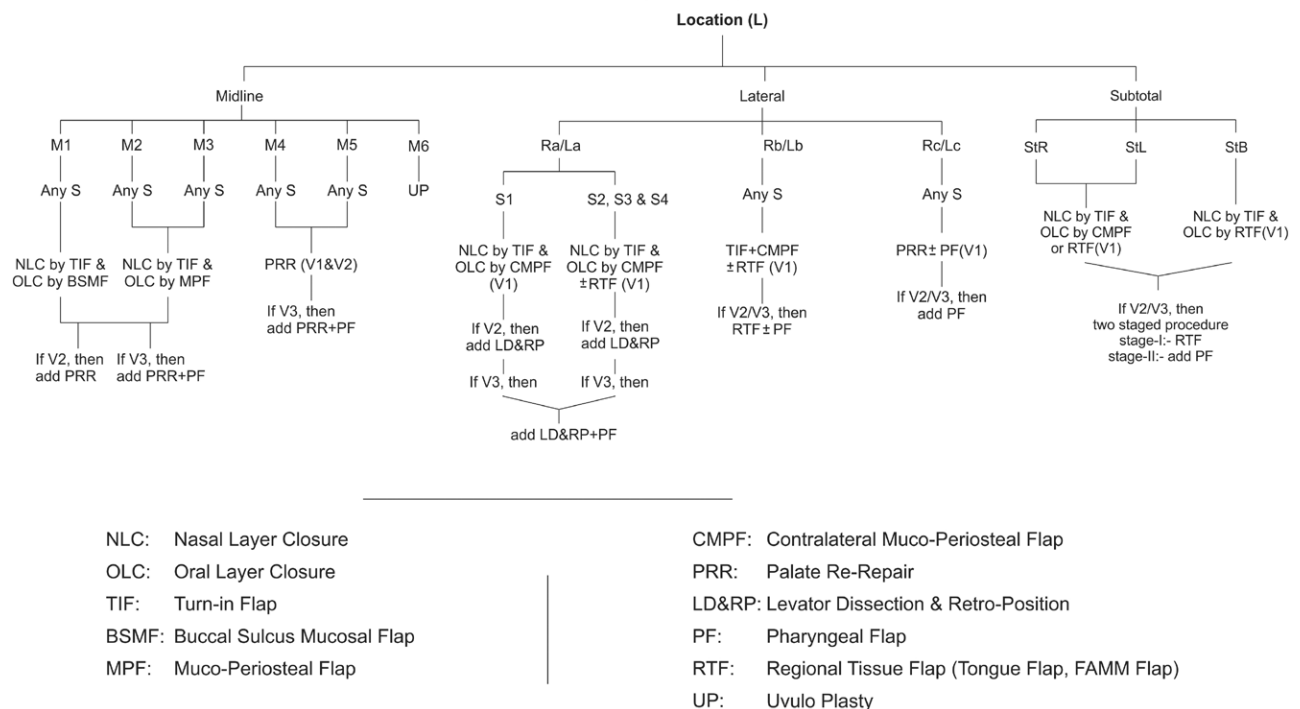


Fig. 4. Algorithm for management of different types of palatal fistulae.

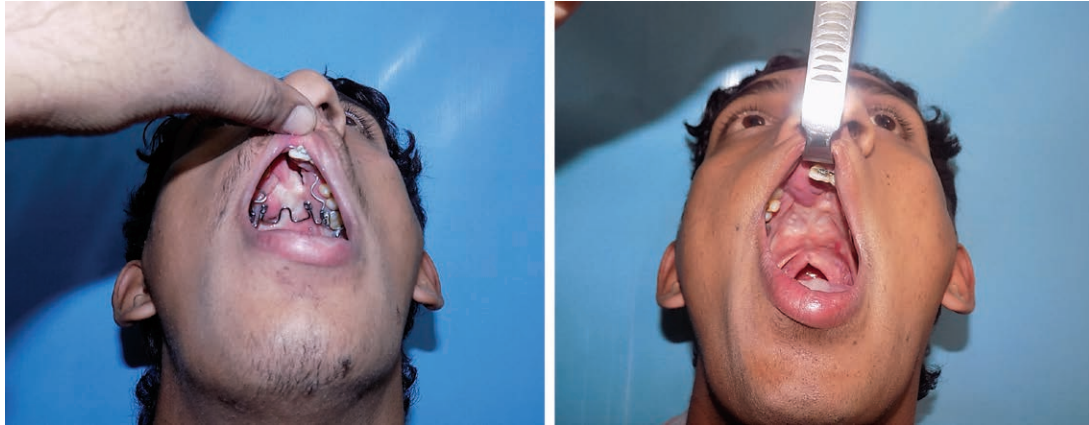

Fig. 5. (Left) A 20-year-old man with a fistula involving M1 and M2, 13 mm in longitudinal dimension with good palatal movement (M1,2 S3 V1). (Right) Repair of the fistula with nasal layer closure by turn-in flap and oral layer closure by buccal sulcus mucosal flap.

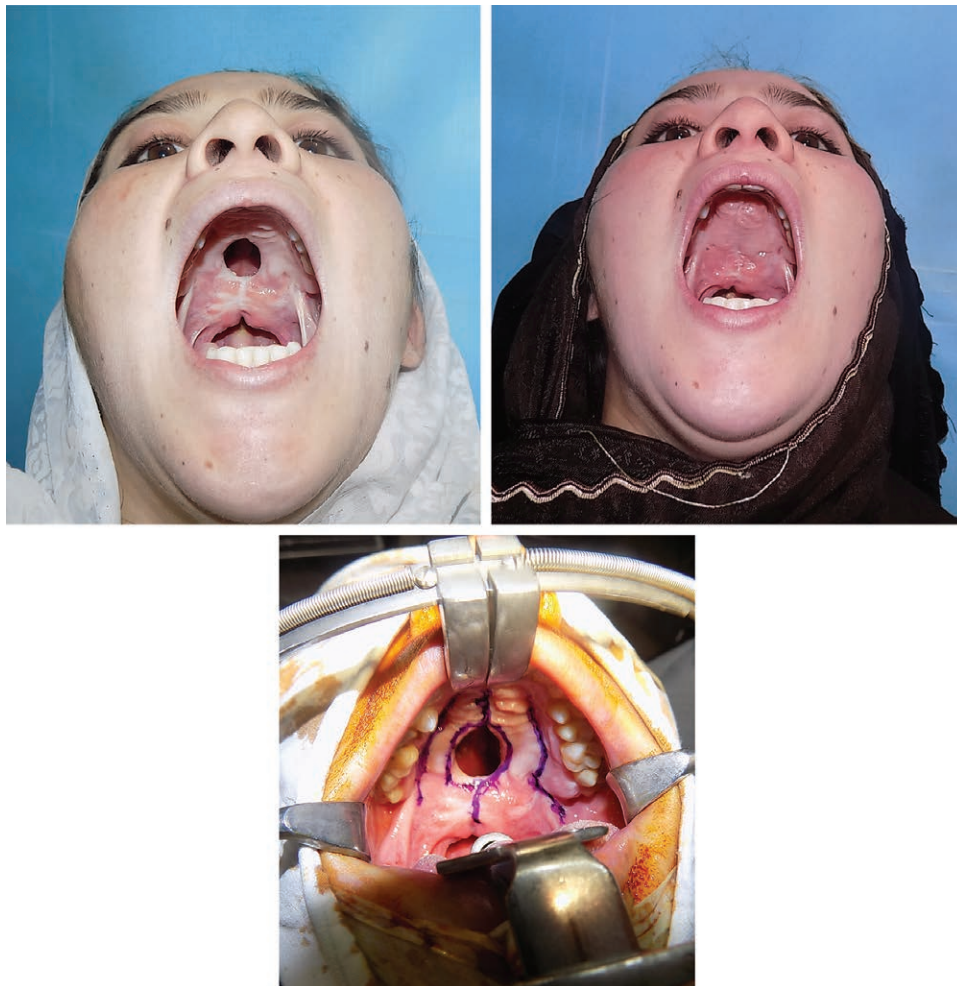

Fig. 6. (Above, left) A 15-year-old girl with a large fistula in the posterior half of the hard palate, 12 × 8 mm, with poor palatal movement (M3 S3 V2). (Below) Marking of the turn-in flap for closure of the nasal layer. (Above, right) Repair of the fistula with a turn-in flap for nasal layer closure and oral layer closure with bilateral mucoperiosteal flaps. Release of the greater palatine artery and repositioning of the levator muscles results in comfortable closure of the oral layer in addition to lengthening of the palate.

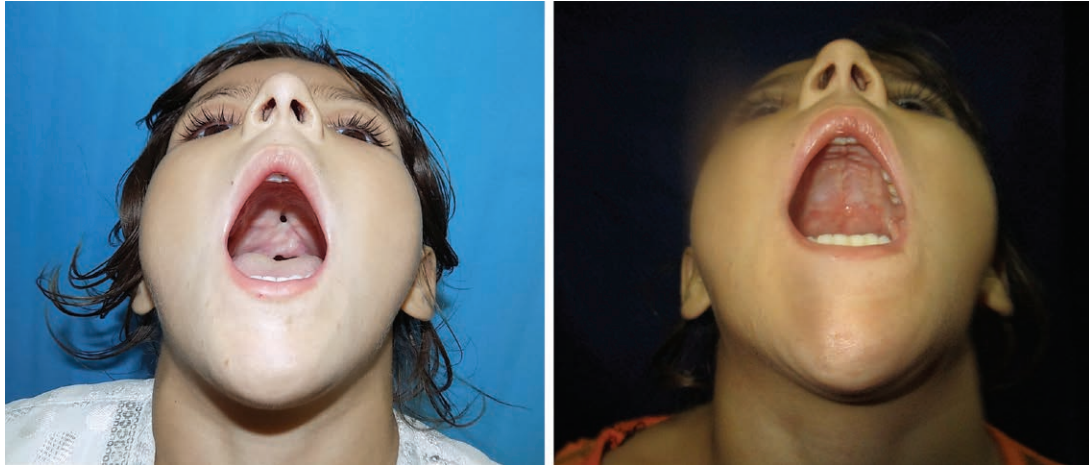

Fig. 7. (Left) A 6-year-old girl with a fistula at the junction of hard and soft palates, 5 mm in the largest dimension, with good palatal movement (M4 S1 V1). (Right) Repair of the fistula with palate rerepair.

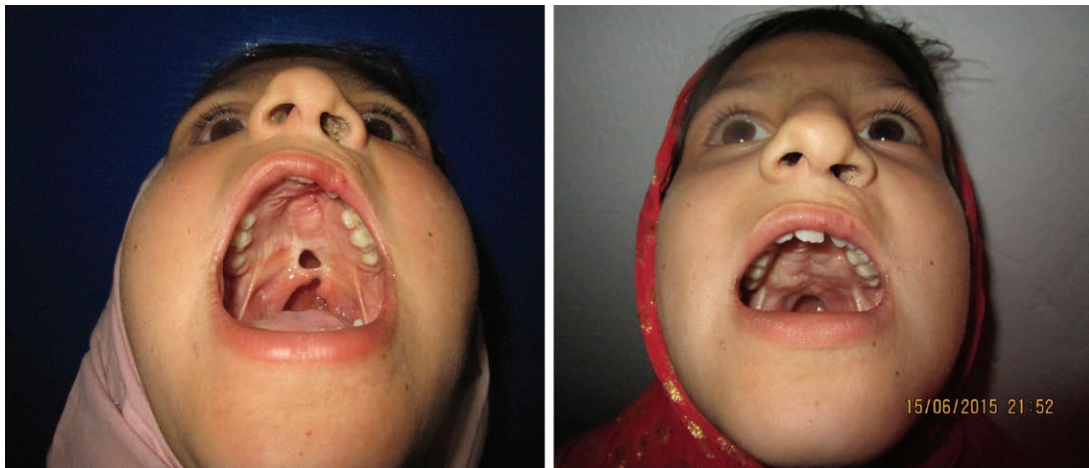

Fig. 8. (Left) A 5-year-old girl with a fistula in the soft palate and dehiscence of the uvula, with reduced movement of the velum (M5 S2 V1-D1). (Right) Repair of the fistula and dehiscence with palate rerepair.

the soft palate (Rc or Lc) of any size indicate soft-tissue deficiency in the region of the soft palate, and this requires palate rerepair with or without the addition of the pharyngeal flap (Fig. 11).

The most difficult fistulae are subtotal fistulae that involve the midline and lateral regions of the anterior palate. [See **Figure, Supplemental Digital Content 2**, which shows an 8-year-old girl with a subtotal type of fistula involving both sides of the hard palate, 25 × 12 mm, with good palatal movement (StB S4 V1). The nasal layer was closed by large turn-in flaps, and the oral layer was closed with a tongue flap, <http://links.lww.com/PRS/D213>.] These fistulae usually result from damage to the pedicle (greater palatine artery) of one or both mucoperiosteal flaps. In such fistulae, nasal layer closure is carried out by large turn-in flaps. Oral layer closure has to be accomplished by

regional tissue flaps such as a tongue flap or facial artery myomucosal flap, or distant tissue transfer such as a radial forearm flap. There may be cases in which one side of the palate is spared, and that mucoperiosteal flap can be mobilized extraordinarily to cover the other side. [See **Figure, Supplemental Digital Content 3**, which shows a 7-year-old boy with a subtotal type of fistula involving the midline and the left side of the hard palate, 21 × 12 mm, with good palatal movement (StL S4 V1). The nasal layer was closed by large turn-in flaps and the oral layer was closed with a contralateral mucoperiosteal flap, <http://links.lww.com/PRS/D214>.] If soft palate movement is poor (V2) and the palate is short as well (V3), the reconstruction has to be staged. In the first stage, repair of the palate is carried out with local or distant tissue and later a pharyngeal flap is added.

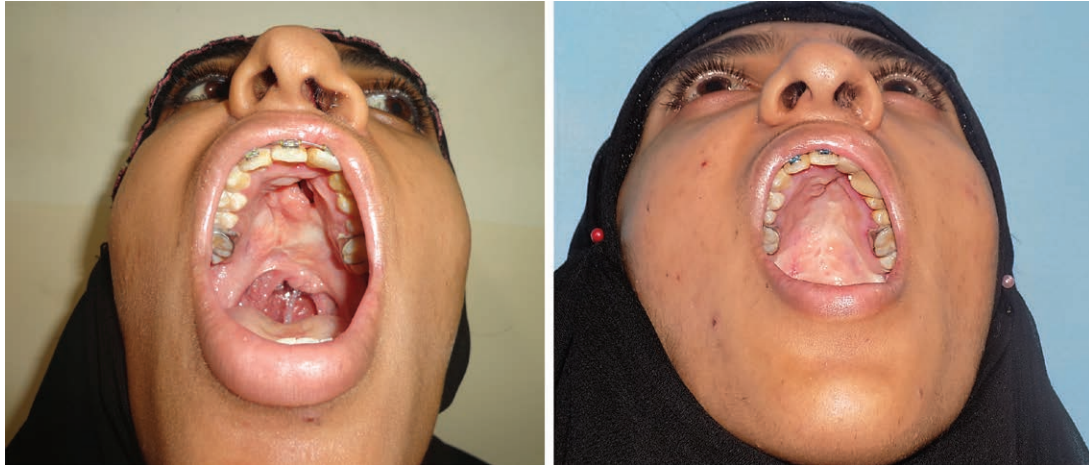

Fig. 9. (Left) An 18-year-old female patient with a lateral fistula involving the anterior half of the hard palate on the left side (La), 14 × 4 mm, with good movement of the palate (La S3 V1). (Right) Repair of the fistula with nasal layer closure by turn-in flaps and oral layer closure by contralateral mucoperiosteal flap.

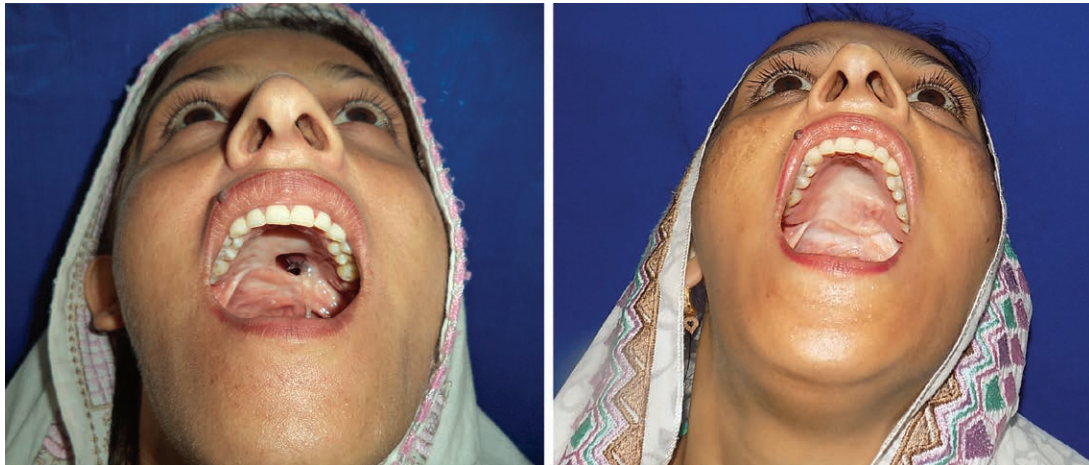

Fig. 10. (Left) A 23-year-old woman with a lateral fistula in the posterior half of the hard palate on the left side (Lb), 12 × 8 mm, with good movement of the palate (Lb S3 V1). (Right) Repair of the fistula with nasal layer closure by turn-in flaps and oral layer closure by a contralateral mucoperiosteal flap.

For multiple fistulae involving different locations, the fistulae have to be closed according to the algorithm. Management of smaller fistulae is relatively easy with palate rerepair. [See **Figure, Supplemental Digital Content 4**, which shows a 22-year-old man with two fistulas, one in the anterior hard palate and the other in the soft palate. These fistulae would be described as MF = F1(M2 S1 V1) F2(M5 S1 V1). Both of them were managed with palate rerepair, <http://links.lww.com/PRS/D215>.] Rarely, subtotal defects may be encountered in which there are other fistulae as well (Fig. 12, left). In such cases, a free flap is usually required, as it provides adequate tissue for reconstruction. A large tongue flap can also be used to reconstruct the oral layer, as shown in Figure 12, right.

Certain situations may arise when there is dehiscence of the soft palate in addition to fistula in the hard palate. In such cases, if there is only dehiscence of the uvula (D1), uvuloplasty along with fistula closure can suffice. If there is dehiscence of the soft palate (D2), rerepair of the soft palate with repositioning of the muscles can be attempted. If the dehiscence involves both the hard and soft palates (D3), rerepair of the palate in its entirety may be the solution. [See **Figure, Supplemental Digital Content 5**, which shows a 6-year old girl with dehiscence of the soft palate and posterior hard palate (D3) managed with palate rerepair technique, <http://links.lww.com/PRS/D216>.] If the whole palate is dehiscenced (D4), rerepair of the palate with addition of some local or

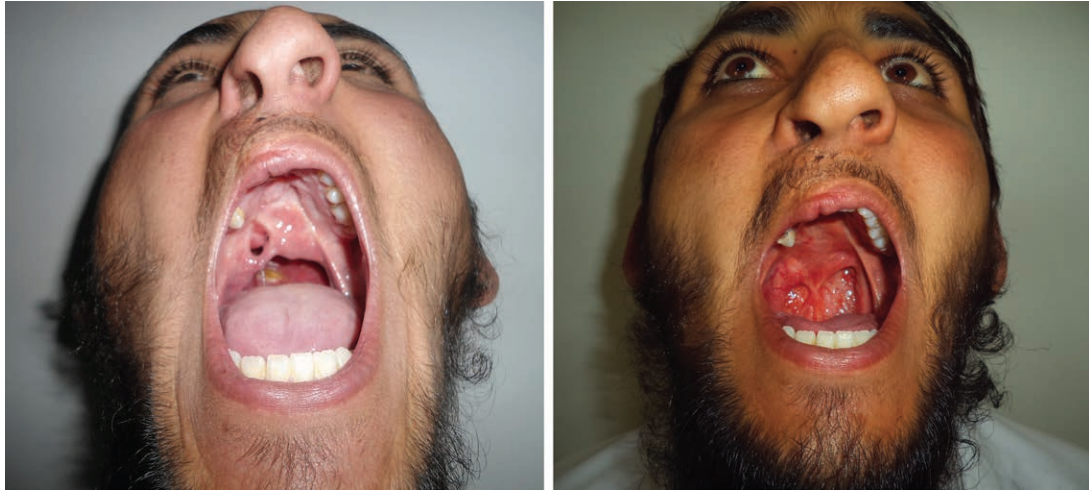

Fig. 11. (Left) A 26-year-old man with a lateral fistula of soft palate on the right side (Rc), 7 × 6 mm, with reduced movement of the palate (Rc S2 V3). (Right) Repair of the fistula with palate rerepair and a pharyngeal flap.

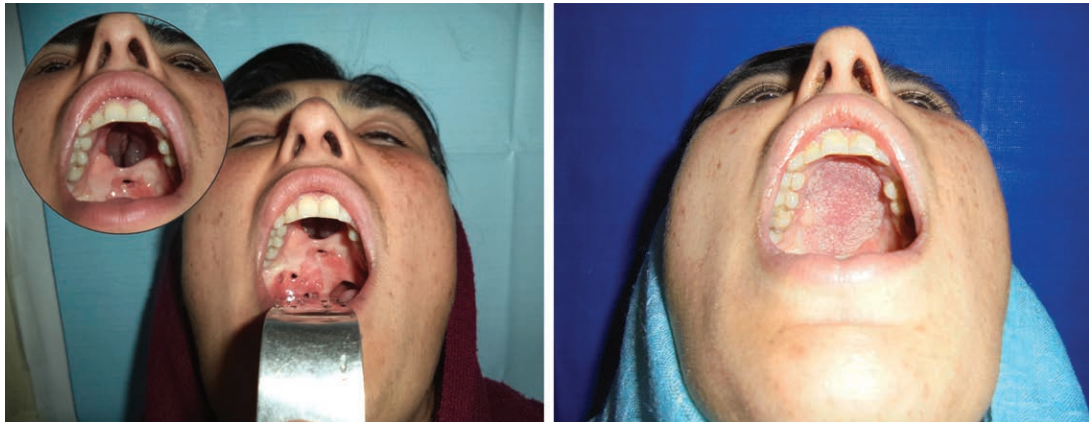

Fig. 12. (Left) A 19-year-old female patient presented with multiple fistulae with an already-executed pharyngeal flap. A very large fistula is present in the hard palate involving greater than 50 percent of the hard palate bilaterally. The second fistula is in the M4 area, and a small fistula is also present in the soft palate as well. These fistulae would be described as MF = F1(StB S4 V1), F2(M4 S2 V1), F3(Rc S2 V1). (Right) The subtotal fistula was managed with closure of the nasal layer with large turn-in flaps, and the oral layer cover was provided by a large tongue flap in the first stage. During detachment, some extra tissue was taken from the tongue to cover both F2 and F3 after nasal layer closure.

regional tissues may be needed. In cases where there is dehiscence along with loss of tissue on any side (D3L/R), a contralateral mucoperiosteal flap can be helpful, or we may have to go for regional tissue flaps to cover the oral layer. [See **Figure, Supplemental Digital Content 6**, which shows a 12-year-old boy with dehiscence of the soft and hard palates, with loss of tissue of the posterior hard palate on the right side (D3R). Rerepair of the palate with nasal layer closure by turn-in flaps and oral layer closure by contralateral mucoperiosteal flap was performed, <http://links.lww.com/PRS/D217>.]

RESULTS

Over a period of 15 years, the senior author (G.Q.F) and his team have treated 2537 patients with palatal fistula and dehiscence. Their age ranged from 1 to 48 years (mean age, 6 years). There were 1347 male patients and 1190 female patients. There were 2258 midline, 208 lateral, and 53 subtotal fistulae. Eighteen patients with dehiscence were included in the study. The exact location of fistulae is shown in Table 1. The size of different fistulae is shown in Table 2. Table 3 elaborates the status of velopharyngeal competence of these patients. The surgical procedures

Table 1. Location of Different Fistulae

Location	No. (%)
Midline	
Total	2258 (89)
M1	164 (7.3)
M2	59 (2.6)
M3	624 (27.6)
M4	856 (37.9)
M5	512 (22.6)
M6	14 (0.6)
FAR	29 (1.3)
Lateral	
Total	208 (8.2)
La	109 (52.4)
Lb	18 (8.6)
Lc	3 (1.4)
Ra	66 (31.9)
Rb	10 (4.7)
Rc	2 (1.0)
Subtotal	
Total	53 (2.1)
StL	32 (59.8)
StR	16 (31.2)
StB	5 (9.0)

Table 2. Size of Different Groups of Fistulae According to Location

Location	No.	Average Size (mm)	Range (mm)	S1	S2	S3	S4
Midline	2258	6	3–19	890	708	489	171
Lateral	208	11.8	8–21	0	67	123	18
Subtotal	53	19	12–42	0	0	15	38

carried out for different fistulae are shown in Tables 4 through 6. A total of 181 patients developed recurrence (7.3 percent). The fistula recurrence was 7.0 percent in the midline, 9.6 percent in the lateral, and 12.0 percent in the subtotal fistulae. Speech assessment of 942 patients aged 4 years or older was carried out at 6-month follow-up using the Mary Burger speech scale. These patients showed improved velopharyngeal competence in the form of reduction of hypernasality and improved propulsive consonant production. However, articulatory errors were observed in older patients.

DISCUSSION

Palatal fistulae continue to plague the success of primary palatal repair. The repair of palatal fistula presents one of the most challenging situations to the cleft surgeons. Even after fistula repair, recurrence rates can be as high as 96 percent.⁷ Fistula management requires comprehensive assessment of the fistula and function of the palate to devise a safe and effective surgical plan.

Table 3. Status of Function of Velum as Assessed by a Speech Pathologist

Location of Fistula	No.	V1 (%)	V2 (%)	V3 (%)
Midline	2258	792 (35.0)	1243 (55.0)	223 (9.9)
Lateral	208	16 (7.7)	148 (71.1)	44 (21.1)
Subtotal	53	27 (50.9)	15 (28.3)	11 (20.7)
Total	2519	835 (33.1)	1406 (55.7)	278 (11.0)

Table 4. Procedures Performed for Midline Fistulae (n = 2258)

Location of Fistula	No.	BSMF	MPF	Uvuloplasty	PRR plus Fistula Closure	PRR plus PF
M1	164	155			9	10
M2	59		49			10
M3	624		565			59
M4	856				741	115
M5	512				475	37
M6	14			14		
FAR	29		9		18	2

BSMF, buccal sulcus mucosal flap; MPF, mucoperiosteal flap; PRR, palate rerepair; PF, pharyngeal flap.

Table 5. Procedures Performed for Lateral Fistulae (n = 208)

Location of Fistula	No.	CMPF	CMPF plus LD/RP	CMPF plus LD/RP plus PF	PRR plus PF
Ra	66	4	52	10	
Rb	10	3	4	3	
Rc	2				2
La	109	7	81	21	
Lb	18	2	11	5	
Lc	3				3

CMPF, contralateral mucoperiosteal flap; LD, levator dissection; RP, retro position; PF, pharyngeal flap; PRR, palate rerepair.

Table 6. Procedures Performed for Subtotal Fistulae (n = 53)

Location of Fistula	No.	CMPF	CMPF plus LD and RP	CMPF plus PF	RTF	Two-Stage
StR	16	5	3	2	1	5
StL	23	8	7	3	2	12
StB	5				1	4

CMPF, contralateral mucoperiosteal flap; LD, levator dissection; RP, retro position; PF, pharyngeal flap; RTF, regional tissue flap.

To date, very few classifications are available in the literature. Cohen et al.¹ and Folk et al.⁸ tried to describe fistulae of the palate based on their location. Smith et al.⁹ popularized the Pittsburgh classification system based on numerical allocation to the fistulae at seven zones in the midline. There are many limitations of these classifications. Only

midline fistulae are described, and these are useful in single, small fistula, as size of the fistula is not considered. In the Pittsburgh classification, function of the palate was defined by a suffix, +/-, which avoids objective assessment of soft palate function.

Another classification was proposed by Richardson and Agni¹⁰ that takes into account the “difficulty index” of the fistula. This classification divides the fistulae into longitudinal and transverse. This classification does not address the multiplicity of the fistula. Moreover, the many other confounding factors that relate to complexity of reconstruction such as type of the cleft, previous surgical technique, pedicle dissection, age of the patient, number of previous operations and, most importantly, the experience and expertise of the surgeon are not taken into account.

The senior author and his team have operated on 14,000 cleft palate patients over the past 15 years and have come across over 2500 fistulae. Many of these fistulae did not fit into any of the prevailing classification systems. The presented classification not only clearly describes the exact anatomy of the fistula, but also gives an insight into how this fistula might have formed, as fistulae in different regions of the palate have different causes. This helps in formulating a thorough treatment plan as explained in the algorithm. It also addresses the function of the palate, as velopharyngeal competence has been included in this classification. In our view, the structure and function of the palate are interrelated. Mere closure of the hole in the palate will not lead to proper speech if the soft palate is not functioning properly. It may also be of interest to note that we have suggested mucoperiosteal flap dissection in any fistula of the hard palate (M2, M3, or M2-3) or palate rerepair in M4 and M5, as the fistulae occurring in this region most commonly occur as a result of inadequate dissection and release of the greater palatine artery. We believe that proper release of the greater palatine artery results in excessive mobility of the mucoperiosteal flap, which allows a tension-free repair.¹¹

One of the fallacies noted in the previous classification systems is taking the incisive foramen as a landmark for location of the fistula. There is no incisive foramen in a patient with complete cleft palate, as the bone is absent in cleft area. It is for this reason that interpersonal variability of the location of fistula in this region is a common occurrence.¹² We have divided the hard palate into anterior and posterior halves, which in our view is more practical and objective.

The algorithm presented in the present study is based on 15 years of experience of the senior author (G.Q.F). We have attempted to simplify the management of palatal fistula in its entirety. Closure of a fistula is not the only goal, as velopharyngeal competence is also assessed (Table 3). The basis of fistula treatment in most of these patients is palate rerepair in which radical release of the greater palatine artery is carried out with repositioning of the muscles in the soft palate. This results in improvement of velopharyngeal competency, which in our view is of utmost importance. There are some limitations of the study. Objective assessment of velopharyngeal incompetence has not been carried out. Evaluation by videofluoroscopy or nasoendoscopy would have been a better approach. Similarly, regarding the management of M1 fistula, the majority of the surgeons should wait until the patient was aged 9 years to close the fistula during an alveolar bone grafting procedure. The treatment of fistulae of the lateral palate and subtotal loss is sparse in literature.¹³ We have treated a large number of such cases with successful outcome. Nevertheless, this is one of the areas where different surgeons may consider other options to be more appropriate, and there is still room for improvement.

CONCLUSIONS

We present a novel classification scheme to describe palatal fistulae, which takes into account the less commonly seen lateral fistulae and the function of the palate as well. In addition, we propose a treatment algorithm, based on this classification.

Ghulam Qadir Fayyaz, M.B.B.S., D.S.S., M.S.

Department of Plastic Surgery
Services Institute of Medical Sciences and CLAPP Hospital
932-C, Faisal Town
Maulana Shaukat Ali Road
Lahore, Punjab 54700, Pakistan
gqfayyaz@hotmail.com

ACKNOWLEDGMENT

The authors are grateful to Hermann F. Sailer, M.D., founder/chairman of Cleft Children International, Zurich, Switzerland, for supervision and guidance of our Cleft Program in Pakistan and Afghanistan.

PATIENT CONSENT

Patients or parents or guardians provided written consent for use of patients' images.

REFERENCES

1. Cohen SR, Kalinowski J, LaRossa D, Randall P. Cleft palate fistulas: A multivariate statistical analysis of prevalence, etiology, and surgical management. *Plast Reconstr Surg*. 1991;87:1041–1047.
2. Amaratunga NA. Occurrence of oronasal fistulas in operated cleft palate patients. *J Oral Maxillofac Surg*. 1988;46:834–838.
3. Muzaffar AR, Byrd HS, Rohrich RJ, et al. Incidence of cleft palate fistula: An institutional experience with two-stage palatal repair. *Plast Reconstr Surg*. 2001;108:1515–1518.
4. Diah E, Lo LJ, Yun C, Wang R, Wahyuni LK, Chen YR. Cleft oronasal fistula: A review of treatment results and a surgical management algorithm proposal. *Chang Gung Med J*. 2007;30:529–537.
5. Sommerlad BC. A technique for cleft palate repair. *Plast Reconstr Surg*. 2003;112:1542–1548.
6. Fayyaz GQ, Gill NA, Ishaq I, et al. A model humanitarian cleft mission: 312 cleft surgeries in 7 days. *Plast Reconstr Surg Glob Open* 2015;3:e313.
7. Bardach J, Morris H, Olin W, McDermott-Murray J, Mooney M, Bardach E. Late results of multidisciplinary management of unilateral cleft lip and palate. *Ann Plast Surg*. 1984;12:235–242.
8. Folk SN, D'Antonio LL, Hardesty RA. Secondary cleft deformities. *Clin Plast Surg*. 1997;24:599–611.
9. Smith DM, Vecchione L, Jiang S, et al. The Pittsburgh Fistula Classification System: A standardized scheme for the description of palatal fistulas. *Cleft Palate Craniofac J*. 2007;44:590–594.
10. Richardson S, Agni NA. Palatal fistulae: A comprehensive classification and difficulty index. *J Maxillofac Oral Surg*. 2014;13:305–309.
11. Fayyaz GQ, Gill NA, Chaudry A, et al. Radical dissection of greater palatine artery and dynamic reconstruction of cleft palate. *Plast Reconstr Surg Glob Open* 2017;5:e1235.
12. Emory RE Jr, Clay RP, Bite U, Jackson IT. Fistula formation and repair after palatal closure: An institutional perspective. *Plast Reconstr Surg*. 1997;99:1535–1538.
13. Chen HC, Ganos DL, Coessens BC, Kyutoku S, Noordhoff MS. Free forearm flap for closure of difficult oronasal fistulas in cleft palate patients. *Plast Reconstr Surg*. 1992;90:757–762.